

Heineke-Mikulicz and Finney Strictureplasty in Crohn's Disease

Carl J. Brown, MD, MSc, FRCSC

Most patients with Crohn's disease will undergo at least one surgical resection of their small bowel, large bowel, or both, as part of the treatment of their illness.¹ Although the emergence of medical therapies may defer or avoid surgical interventions in some of these patients, many will still undergo multiple surgical procedures.^{2,3} The perils of multiple bowel resections, ranging from subtle nutritional deficits to full parenteral nutritional dependence, have led to the development of bowel-conserving surgical strategies. Small bowel stricture (Fig 1) is a manifestation of Crohn's disease that is amenable to nonresectional surgery.

In 1982, Lee and Papaioannou published a study of nine patients treated successfully with strictureplasty.⁴ Subsequently, two separate reviews have described successful outcomes in nearly 1,000 patients with Crohn's disease who have undergone strictureplasty for fibrotic strictures with a complication rate of approximately 10%.^{5,6} Nearly half of these complications were subsequent abscess, fistulae, or both.

The Heineke-Mikulicz (H-M) strictureplasty, the eponymous description of the longitudinal incision and subsequent transverse closure of the bowel lumen that expands the diameter of the strictured segment, comprised 85% of the reported strictureplasties.⁶ The H-M is used in strictures that are less than 10 cm in length. The Finney strictureplasty, which is essentially a side-to-side hand sewn anastomosis, is the next most common strictureplasty technique and is utilized for most of the remaining 15% of strictures that are too long for a H-M approach.⁶ Generally, the Finney is used in strictures 10 to 25 cm in length.

Indications

Crohn's disease associated small bowel fibrotic strictures up to 25 cm in length can be considered for strictureplasty. Although patients with previous bowel resections are usually considered for this bowel-conserving technique, patients with strictures as the first presentation of Crohn's disease are also candidates for nonresectional surgical approach especially if they have multiple short strictures. Strictureplasty should be utilized in duodenal strictures, if possible rather than a gastrojejunostomy. Strictures at a previous anastomo-

sis can be considered for strictureplasty if the resultant anatomic configuration is amenable to this approach.

Contraindications to strictureplasty include local sepsis (ie, perforation, abscess, or fistula), close proximity to a segment requiring resection and unfavorable anatomy.

Procedure

In patients with obstructive symptoms from Crohn's related stricture, extensive preoperative investigation is critical for operative planning. Upper gastrointestinal barium studies with small bowel follow through can identify single or multiple strictures. Colonoscopy should be used to rule out colonic disease, stricture, or both. Finally, most patients should undergo computed tomography scan of the abdomen and pelvis to rule out localized perforation and abscess.

Exploratory laparotomy with mobilization of the entire small bowel is the first step in treating Crohn's-related strictures. Identification and isolation of an appropriate stricture segment (or segments) should follow (Fig 2).

H-M Strictureplasty

When a small bowel stricture that is less than 10 cm long is identified, H-M strictureplasty is preferred. The segment is isolated and nontraumatic bowel clamps are placed proximal and distal to the segment. Two stay sutures (2-0 absorbable suture) are placed at the midpoint of the stricture on either side of the intended incision line. Along the antimesenteric border, a longitudinal incision is made through the full length of the stricture.

To ensure additional local strictures are not missed, the index finger, a Foley catheter, or both, should be passed through the enterotomy site to evaluate the luminal diameter both proximal and distal to the main stricture (Fig 3).

Finally, the enterotomy is closed with a single layer of interrupted 2-0 absorbable seromuscular stitches placed 2 to 3 mm apart.

Finney Strictureplasty

In situations where the stricture length exceeds 10 cm, simple H-M strictureplasty usually cannot be performed. After applying nontraumatic bowel clamps proximally and distally, the stricture segment is folded in half with its midpoint at the apex of the

From the Division of Surgery, St. Paul's Hospital, Vancouver, BC, Canada. Address reprint requests to Carl J. Brown, MD, MSc, FRCSC, Division of Surgery, St. Paul's Hospital, 1081 Burrard Street, Rm c310, Vancouver, BC V6Z 1Y6. E-mail: cbrown@providencehealth.bc.ca

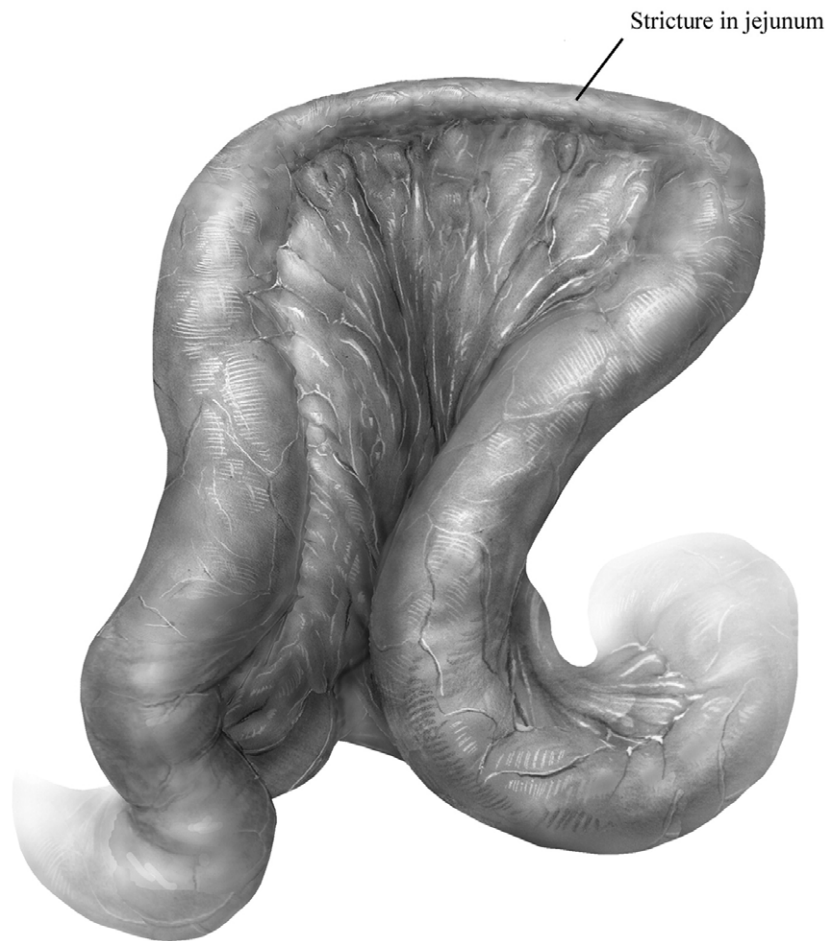

Figure 1 Small bowel Crohn's disease. Segment of small bowel demonstrating fibrotic stricture.

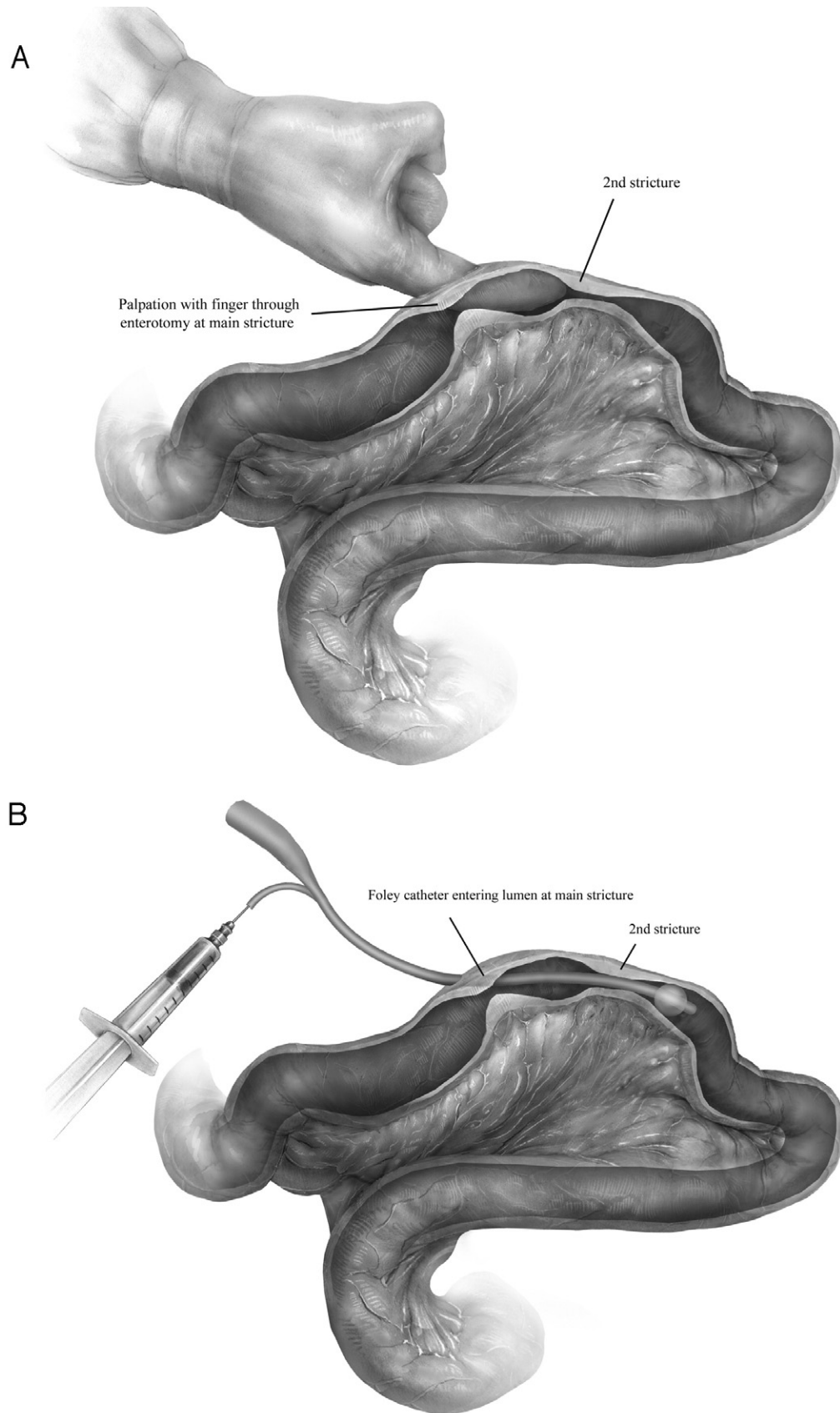


Figure 2 Evaluation for multiple strictures. After careful palpation of the small bowel near the predominant stricture, intraluminal evaluation of the proximal and distal segments close to the planned strictureplasty is necessary. (A) Simple digital evaluation by passing the index finger proximal and distal to the enterotomy can detect unexpected additional strictures. (B) Similarly, to evaluate areas further than a finger can reach, a 18 French Foley catheter is inserted through the enterotomy to its full length and the balloon inflated. The catheter is then slowly withdrawn and areas of stricture can be identified when the catheter's path is impeded. The size of these strictures can be assessed by slowly deflating the balloon and partially re-inflating it in the middle of the stricture.

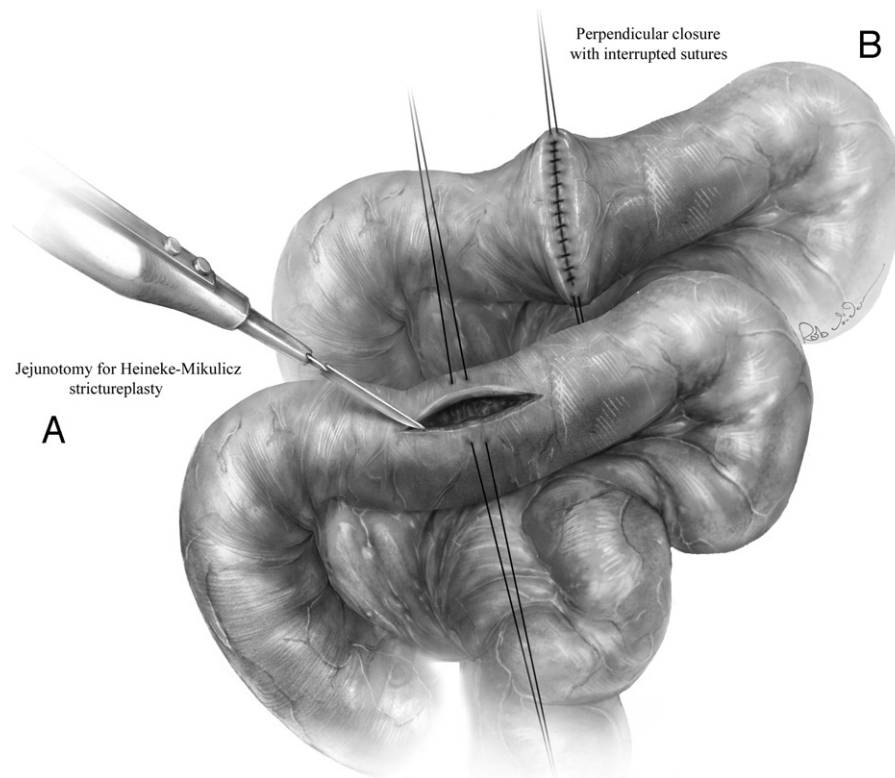


Figure 3 Heineke-Mikulicz strictureplasty. (A) A longitudinal incision through the stricture along the antimesenteric border of the bowel is the first step in the procedure. Stay sutures are placed on either side of the incision at the midpoint of the enterotomy to retract the edges and facilitate transverse closure. (B) A series of interrupted absorbable 2-0 sutures are used close the enterotomy.

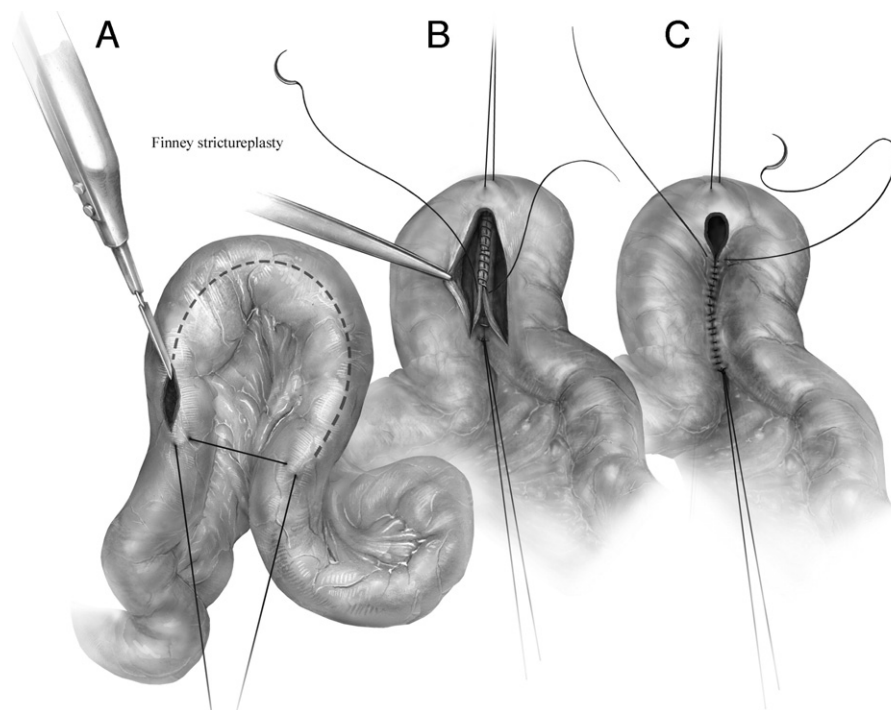


Figure 4 Finney Strictureplasty. (A) The small bowel containing the stricture is brought together in a side-to-side U configuration. A longitudinal incision is made through the length of the stricture along the anti-mesenteric border of the bowel. A stay suture is used to approximate each end of the stricture to maintain the U configuration. (B) A second stay suture is placed at the midpoint of the incision at the apex of the U loop. An absorbable 2-0 suture is run from the midpoint of the incision to the ends of the original incision. (C) Once the corner is passed, the anastomosis is completed by suturing the front wall of the small bowel with the same running suture. A second absorbable 2-0 suture is run from the other midpoint of the original incision (apex of the U loop) to meet the first suture.

U shaped loop (Fig 4A). A stay suture (2-0 absorbable stitch) is placed at the apex of the U shaped loop. A second stay suture is placed just distal and proximal to the stricture segment to maintain the loop configuration (Fig 4A).

Using electrocautery, a longitudinal incision is created along the antimesenteric border of the strictured segment. Starting at the apex of the deep aspect of the enterotomy, the back wall of the anastomosis is closed with a running full thickness 2-0 absorbable suture (Fig 4B). This running suture is continued until the corner of the new anastomosis is passed; thereafter, a second 2-0 absorbable suture is started at the opposite corner of the new anastomosis and run to meet the first stitch (Fig 4C). The two sutures are tied together to complete the anastomosis. The stay suture at the join of the proximal and distal points of the original stricture can be tied to help support this corner of the suture line.

Summary

Patients with Crohn's related strictures can be treated effectively with strictureplasty. Most strictures are amenable to

either H-M or Finney strictureplasty techniques. Utilization of these strategies can preserve functional small bowel and may prevent nutritional complications related to inadequate residual small bowel.

References

1. Whelan G, Farmer RG, Fazio VW, et al: Recurrence after surgery in Crohn's disease. Relationship to location of disease (clinical pattern) and surgical indication. *Gastroenterology* 88:1826-1833, 1985
2. Bernstein CN, Nabalamba A: Hospitalization, surgery, and readmission rates of IBD in Canada: A population-based study. *Am J Gastroenterol* 101:110-118, 2006
3. Vind I, Riis L, Jess T, et al: Increasing incidences of inflammatory bowel disease and decreasing surgery rates in Copenhagen City and County, 2003-2005: A population-based study from the Danish Crohn colitis database. *Am J Gastroenterol* 101:1274-1282, 2006
4. Lee EC, Papaioannou N: Minimal surgery for chronic obstruction in patients with extensive or universal Crohn's disease. *Ann R Coll Surg Engl* 64:229-233, 1982
5. Roy P, Kumar D: Strictureplasty. *Br J Surg* 91:1428-1437, 2004
6. Tichansky D, Cagir B, Yoo E, et al: Strictureplasty for Crohn's disease: Meta-analysis. *Dis Colon Rectum* 43:911-919, 2000